Cardiovasc Intervent Radiol (2026) 49:585–593
https://doi.org/10.1007/s00270-025-04310-5

CLINICAL INVESTIGATION NON-VASCULAR INTERVENTIONS

Interventional Management of Pain with Cryoneurolysis: Expert Consensus Recommendations for Standardizing Patient Selection and Techniques Based on Delphi Process

Francois H. Cornelis[1,2] · Neil J. Resnick[3] · Matthias Barral[4] · Salem Bauones[5] · Jan Fritz[6] · Jeffrey P. Guenette[7] · Jack W. Jennings[8] · Adrian Kastler[9] · Alexis Kelekis[10] · Alexa Levey[11] · Raul Garcia Marcos[12] · Marwan Moussa[13] · Evangelos Petsatodis[14] · Uei Pua[15] · Vijay Ramalingam[13] · Leo Razakamanantsoa[16] · Alan A. Sag[17] · Nicolas Stacoffe[18] · Sean Tutton[19] · Steven Yevich[20] · J. David Prologo[21] · Dimitrios Filippiadis[22,23]

Received: 7 November 2025 / Accepted: 4 December 2025 / Published online: 28 December 2025
© Springer Science+Business Media, LLC, part of Springer Nature and the Cardiovascular and Interventional Radiological Society of Europe (CIRSE) 2025

Abstract

Purpose To develop expert consensus recommendations for patient selection and procedural techniques in cryoneurolysis for chronic pain management using a Delphi process.

Materials and Methods A panel of 22 international interventionists participated in a two-round Delphi process. Participants rated 42 statements on a 10-point Likert scale (1 = strongly disagree, 10 = strongly agree). Consensus was predefined as ≥ 75% of ratings ≥ 7. Descriptive statistics (n, mean ± SD, % ≥ 7) were calculated.

Results High agreement supported cryoneurolysis for localized chronic pain refractory to conservative therapies (mean 8.55 ± 0.60; 100% ≥ 7) and cases with identifiable

✉ Francois H. Cornelis
cornelif@mskcc.org

1 Department of Radiology, Memorial Sloan Kettering Cancer Center, 1275 York Avenue, New York, NY 10065, USA

2 Weill Cornell Medical College, 1300 York Avenue, New York, NY 10065, USA

3 Department of Radiology, Division of Interventional Radiology, UMass Memorial Medical Center and Chan Medical School, 55 Lake Ave N, S2-817A, Worcester, MA 01655, USA

4 Université Versailles Saint-Quentin en Yvelines - Paris-Saclay, Radiologie, Hôpital NOVO - Site de Pontoise, Pontoise, France

5 Interventional Radiology Administration, King Fahad Medical City, 11525 Riyadh, Saudi Arabia

6 Department of Radiology, Grossman School of Medicine, New York University, 660 1St Ave, New York, NY 10016, USA

7 Division of Neuroradiology, Brigham and Women's Hospital, Boston, MA 02115, USA

8 Mallinckrodt Institute of Radiology, Washington University School of Medicine, 510 S Kingshighway Blvd, Box 8131, St Louis, MO 63110, USA

9 Interventional and Diagnostic Neuroradiology Unit, University Hospital CHUGA, Grenoble, France

10 Department of Radiology, Attikon General University Hospital, Rimini Athens, 124 62 Chaidari, Greece

11 Yale School of Medicine Department of Radiology and Biomedical Imaging, New Haven, CT 06520, USA

12 Clínical Area of Medical Imaging and Biomedical Imaging Research Group (GIBI230), Hospital Universitario y Politécnico La Fe - Instituto de Investigación Sanitaria La Fe, Valencia, Spain

13 Division of Vascular and Interventional Radiology, Department of Radiology, Beth Israel Deaconess Medical Center/Harvard Medical School, 1 Deaconess Rd, Boston, MA 02215, USA

14 Department of Interventional Radiology, G. Papanikolaou General Hospital, Thessaloniki, Greece

15 Department of Diagnostic Radiology, Tan Tock Seng Hospital, 11 Jalan Tan Tock Seng, Singapore 309199, Singapore

16 Sorbonne University, APHP, Department of Diagnostic and Interventional Radiology, Tenon Hospital, 4 Rue de La Chine, 75020 Paris, France

17 Department of Interventional Radiology, University of Miami, Miami, FL 33131, USA

18 Department of Radiology, Groupement Hospitalier Sud, Hospice Civils de Lyon, Lyon, France

CVIR The official journal of the Cardiovascular and Interventional Radiological Society of Europe
CardioVascular and Interventional Radiology
Springer CORSE

Interventional Management of Pain with Cryoneurolysis: Expert Consensus Recommendations for Standardizing Patient Selection and Techniques Based on Delphi Process

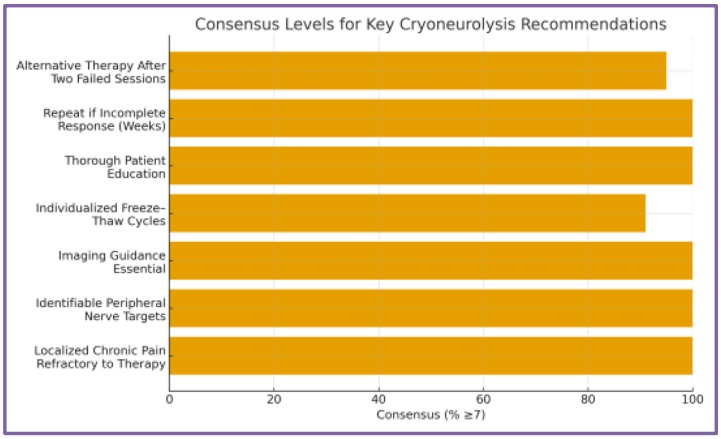

This Delphi study establishes expert-derived consensus standards for cryoneurolysis, highlighting careful patient selection, mandatory imaging guidance, and flexible freeze protocols while identifying areas requiring further research.

peripheral nerve targets (8.45 ± 0.74; 100% ≥ 7). Imaging guidance was deemed essential for nerve identification and probe placement (8.91 ± 0.29; 100% ≥ 7). The panel endorsed individualized freeze–thaw cycles to achieve Sunderland II injury (8.27 ± 0.83; 91% ≥ 7) and emphasized thorough patient education (9.0 ± 0.0; 100% ≥ 7). Experts recommended repeat cryoneurolysis within weeks if initial response was incomplete (8.64 ± 0.65; 100% ≥ 7) and alternative therapies after two unsuccessful sessions (8.36 ± 0.73; 95% ≥ 7). No consensus was reached on restricting treatment to a single anatomical region (5.82 ± 2.91; 50% ≥ 7) or routine prophylactic antibiotics (6.27 ± 2.57; 54% ≥ 7).

Conclusion This Delphi study establishes expert-derived consensus standards for cryoneurolysis, highlighting careful patient selection, mandatory imaging guidance, and flexible freeze protocols while identifying areas requiring further research.

Graphical Abstract

Keywords Pain · Cryoneurolysis · Nerve Block · Analgesia · Interventional Radiology · Delphi Consensus

Abbreviations

CT	Computed tomography
MRI	Magnetic resonance imaging
US	Ultrasound
IR	Interventional radiology
SD	Standard deviation
RCT	Randomized controlled trial

Introduction

Percutaneous cryoneurolysis has become an important therapeutic option in interventional radiology, offering minimally invasive chronic pain management amid the ongoing opioid crisis [1–3]. Cryoneurolysis induces a predictable histopathological sequence including transduction disruption, Wallerian degeneration, and axonal regeneration along an intact connective tissue scaffold [4]. The technique has evolved from intraoperative applications to modern image-guided procedures, with efficacy

[19] Department of Radiology, University of California, San Diego, San Diego, CA, USA

[20] Department of Interventional Radiology, Division of Diagnostic Imaging, The University of Texas MD Anderson Cancer Center, 1515 Holcombe Boulevard, Houston, TX 77030, USA

[21] Department of Radiology and Imaging Sciences, Emory University School of Medicine, 1364 Clifton Rd NE, Atlanta, GA 30092, USA

[22] 2nd Department of Clinical Radiology, University General Hospital "ATTIKON", 1 Rimini Str, 12462 Haidari, Greece

[23] Medical School, National and Kapodistrian University of Athens, Athens, Greece

comparable to or exceeding other interventional pain-control methods [5–8]. Advantages over radiofrequency ablation include real-time visualization of the ice ball and less postoperative pain [9]. Imaging advances enable precise targeting of superficial and deep neural structures for neoplastic and non-neoplastic pain, eliminating palpation landmarks or nerve stimulation while enabling documentation of the ablation zone at the − 20 °C isotherm [10].

Despite these advancements, variation in patient selection, procedural protocols, and follow-up has limited standardization [11]. The evidence base consists primarily of single-center case series and retrospective studies with substantial heterogeneity. Randomized controlled trials are scarce with small sample sizes. This fragmented literature, combined with equipment variability (argon, nitrogen, carbon dioxide systems), probe sizes (8–24 gauge), freeze durations (3–10 min), and temperature targets (− 20 °C to -80 °C), makes systematic review challenging. The absence of standardized protocols necessitates expert consensus to guide clinical decision-making. While representing Level 4–5 evidence, expert consensus provides valuable guidance by integrating collective experience from operators across diverse populations. In this two-round Delphi process, 22 international experts developed consensus recommendations for patient selection, imaging guidance, technical parameters, and post-procedure management.

Materials and Methods

A modified Delphi process was conducted with 22 interventional radiologists selected based on: (1) minimum 3 years performing cryoneurolysis, (2) peer-reviewed publications on interventional pain management or ablation, and (3) diverse geographic representation. Participation was primarily North American and European due to response rates and scheduling constraints. A working group of 4 interventional radiologists generated preliminary items, while formal Delphi rounds involved all 22 panelists. One author (F.H.C.) developed an open-ended questionnaire addressing patient selection, procedural considerations, and technical parameters, reviewed by three authors (D.F., J.D.P., N.J.R.) with > 10 years experience. The 22 manuscript authors served as panelists. Responses were collected anonymously and synthesized into thematic domains. The working group resolved discrepancies through discussion. The authors acknowledge that independent dual coding would have strengthened methodological rigor. Panelists rated agreement on a 1–10 Likert scale (1 = strongly disagree, 10 = strongly agree). Consensus was predefined as ≥ 75% scoring ≥ 7. For each item, n, mean ± SD, and % ≥ 7 were calculated. Forty-two statements were evaluated (Table 1, Supplementary Table 1) and grouped by domain (Technique, Patient Selection, Treatment Delivery, Expected Outcomes, Post-Treatment Care).

Results

All 22 panelists completed both rounds. The two-round Delphi process yielded consensus on 39 of 50 statements (78%). Strong agreement was achieved across most technical and patient selection domains, with high mean scores and low variability. Areas without consensus primarily involved treatment limitations (anatomical region restrictions, number of lesions) and prophylactic antibiotic use, reflecting legitimate clinical uncertainty and institutional variability.

Technique

Anesthesia

Panelists supported performing cryoneurolysis under local anesthesia or conscious sedation, reserving general anesthesia for cancer patients or those requiring deeper sedation (86% ≥ 7). The relatively lower agreement reflects variability in patient populations and institutional capabilities. Some experts advocated for general anesthesia for high patient anxiety, significant positional discomfort, multiple nerve targets requiring longer procedures, or deeply located nerves. Others emphasized that maintaining patient responsiveness facilitates real-time physiologic assessment of sensory and motor function to prevent complications. The moderate consensus suggests anesthesia selection should remain highly individualized based on patient factors, procedural complexity, and institutional resources rather than rigid protocols.

Diagnostic Nerve Blocks

Experts agreed that diagnostic nerve blocks prior to cryoneurolysis confirm the target nerve and familiarize patients with expected post-procedural conditions (100% ≥ 7). For cancer pain, direct treatment without preliminary blocks was acceptable (86% ≥ 7). At cryoneurolysis, the panel endorsed lidocaine 1–2% (50–100 mg) for rapid relief and bupivacaine 0.25–0.5% (12.5–50 mg) for longer-lasting analgesia, with optional steroids (dexamethasone or methylprednisolone) to reduce inflammation (90.9% ≥ 7), emphasizing accurate perineural rather than intraneural injection (86% ≥ 7).

Table 1 Summary of Consensus Recommendations. Summary table presenting key consensus agreements grouped by domain for quick reference

Domain	Key consensus recommendations
Patient selection	Reserve cryoneurolysis for localized chronic pain refractory to conservative therapies with identifiable peripheral nerve targets
	Diagnostic nerve blocks recommended to confirm target nerve and familiarize patient with expected post-procedural conditions
	Direct treatment without preliminary block acceptable for cancer pain
	Comprehensive informed consent required covering risks, contraindications, duration of relief, and regeneration expectations
	Absolute contraindications: bleeding disorders, active infection, cold urticaria, cryoglobulinemia, Raynaud's syndrome
Anesthesia & analgesia	Local anesthesia or conscious sedation preferred; general anesthesia reserved for cancer patients or complex cases
	Lidocaine 1–2% for rapid relief; bupivacaine 0.25–0.5% for longer duration with optional steroids
	Perineural rather than intraneural injection mandatory
	Patient education on transient weakness potential and nerve regeneration rates (1–3 mm/day) essential
Technical parameters	Both single and dual freeze–thaw cycles acceptable; adjust for nerve size and vascular heat sinks
	Avoid temperatures below − 80 °C
	Target Sunderland II injury for durable pain relief with predictable regeneration
	Temperature monitoring recommended when available (target: −20 °C to −50 °C at nerve location)
	Neurophysiologic monitoring optional for mixed nerves; not required routinely
	Validate protocols to ensure consistent Sunderland II injury achievement
Imaging guidance	Mandatory precise probe placement under ultrasound, CT, or MRI guidance throughout procedure
	Pre-freeze imaging confirmation of exact nerve location required
	Continuous real-time imaging to monitor ice ball formation and ablation progress
	Probe oriented parallel to nerve with minimal trauma during insertion
	For non-visualizable targets (celiac plexus, stellate ganglion), rely on anatomic landmarks and vascular markers
Tissue protection	Controlled cryogenic energy delivery essential to protect adjacent structures
	Use hydrodissection (saline), balloon displacement, or gas insufflation to separate critical tissues
	Avoid non-target ablation that may cause allodynia or pain exacerbation
	Control freeze duration and monitor ice ball size to prevent over-ablation
	Meticulous sterile technique mandatory for all procedures
Special considerations	When nerve not directly identifiable, lesion-directed cryoablation acceptable for painful masses < 5 cm
	Duration and temperature tailored to individual nerve size and anatomical location
	Awareness of potential side effects: bruising, bleeding, infection, frostbite, alopecia, depigmentation
	Vigilance for rare complication of myonecrosis with abscess formation
Post-procedure management	Track pain relief duration and adjust subsequent protocols based on individual response
	High-resolution imaging only when complications suspected or unexpected symptom changes occur
	Routine imaging in asymptomatic patients not necessary
	Repeat cryoneurolysis within 2–4 weeks appropriate if initial response incomplete
	After two unsuccessful sessions, consider patient refractory and pursue alternative therapies
	Structured follow-up at 1, 4, 12, and 24 + weeks recommended
Quality & outcomes	Operator training, experience, and case volume significantly influence outcomes
	Standardized protocols recommended to reduce variability and improve consistency across centers
	Expected pain relief duration: 5–12 months in 50–60% of appropriately selected patients
	Repeat cryoneurolysis can be performed with comparable efficacy after pain recurrence

Areas without consensus	Restricting treatment to single anatomical region (mean 5.82; 50% agreement)
	Limiting to ≤ 5 lesions or < 2 anatomical regions (mean 5.59; 40.9% agreement)
	Routine prophylactic antibiotics (mean 6.27; 54% agreement)
	These areas reflect legitimate clinical uncertainty requiring individualized risk–benefit assessment

Note All recommendations achieved ≥ 75% expert agreement (score ≥ 7 on 10-point Likert scale) unless otherwise noted. n = 22 international interventional radiologists with expertise in cryoneurolysis and pain management

Cryoneurolysis Technical Parameters

Technically, cryoneurolysis uses dual-tube cryoprobes that circulate carbon dioxide, argon, or liquid nitrogen to create an ice ball at the tip, producing a Sunderland II injury—axonal disruption with preservation of the myelin sheath and endoneurium [8, 12]. Pain conduction is interrupted for weeks to months with predictable regeneration [13–15]. Two probe types are common: tumor-ablation probes (8–17 gauge; argon or liquid nitrogen) and nerve-analgesia probes (14–24 gauge; carbon dioxide or nitrous oxide with integrated neurostimulators for precise targeting) [16]. Treatment typically involves freeze cycles of 3–10 min and temperatures of − 20 °C to − 80 °C. The panel unanimously agreed that no standardized protocol currently exists for cryoneurolysis (100% ≥ 7). While no single protocol achieved universal consensus, experts agreed that both single and dual alternating freeze–thaw cycles are acceptable (77% ≥ 7) with duration adjusted for nerve size and adjacent cold sinks (e.g., arteries). Temperatures below − 80 °C should be avoided (77% ≥ 7) [8]. The lack of consensus on specific durations reflects genuine variability in current practice and equipment, with experts acknowledging that a standardized protocol may be difficult to establish due to variability in nerves, locations, equipment, and other factors (86% ≥ 7). For operators beginning cryoneurolysis, a pragmatic approach includes: (1) single 8–10 min freeze for superficial sensory nerves, (2) dual freeze–thaw cycles (5 min freeze, 3 min thaw, 5 min freeze) for larger mixed nerves, (3) imaging confirmation of ice ball coverage extending 5–10 mm beyond nerve target, and (4) target temperature of − 20 °C to − 50 °C at the nerve location when monitoring is available. Parameters should be adjusted based on equipment specifications, vascular heat sink proximity, and real-time imaging.

Temperature monitoring, when available, confirms adequate freezing (target: − 20 °C to − 50 °C) and reached consensus as recommended practice (100% ≥ 7). However, dedicated temperature probes are not universally available. Most experts rely on imaging visualization and validated protocols. Neurophysiologic monitoring may provide additional safety when treating mixed nerves near motor structures (100% ≥ 7), but is not required for routine sensory nerve cryoneurolysis. Operators should prioritize meticulous imaging guidance and standardized freeze protocols. The panel unanimously emphasized informed consent including discussion of potential transient weakness in mixed nerves and expected regeneration rates of 1–3 mm/day (100% ≥ 7).

Patient Selection

Indications and Target Identification

The analysis showed strong agreement that cryoneurolysis should be considered for patients with localized chronic pain refractory to conservative therapies (100% ≥ 7) and for patients with clearly identifiable peripheral nerve targets (100% ≥ 7). Panelists emphasized that thorough preoperative evaluation is essential to determine the appropriate level of sedation (86% ≥ 7) and to confirm the therapeutic target with diagnostic nerve blocks (100% ≥ 7) [11]. Although cryoneurolysis is sometimes performed for pain recurrence following chemical interventions, the panel agreed it can be the initial treatment once a diagnostic block is positive (86% ≥ 7), reflecting its precision and low risk of neuroma formation.

Treatment Extent Limitations

Several limiting criteria did not achieve consensus. Restricting treatment to a single anatomical region received moderate support (50% ≥ 7), and treating no more than five lesions or fewer than two regions failed to meet threshold (40.9% ≥ 7). The literature and panel discussion noted that tumors larger than 5 cm often respond poorly due to multiple nerve branches and excessive treatment volume, making them better suited for tumor cryoablation or intra/peritumoral nerve blocks [17, 18]. The lack of agreement reflects heterogeneous chronic pain presentations and competing clinical priorities. Experts supporting restrictions cited concerns about procedure duration, anesthesia safety, and excessive sensory changes compromising patient function [19]. Those opposing restrictions

noted that pain often involves multiple nerve distributions, particularly in cancer patients with complex patterns or widespread conditions like post-herpetic neuralgia affecting multiple dermatomes [20]. The panel recognized that rigid anatomical limitations could unnecessarily restrict treatment of legitimate multi-focal pain while acknowledging that extensive procedures require careful risk–benefit analysis and may be better staged across multiple sessions.

Informed Consent and Contraindications

The panel unanimously agreed that informed consent must cover all potential risks and contraindications, including inability to consent, anatomic barriers, bleeding disorders, coagulopathy, active infection at the treatment site, cold urticaria, cryoglobulinemia, and Raynaud's syndrome (100% $\geq$ 7). Informed consent should address expected pain relief duration (typically 5–12 months), possibility of incomplete response, potential transient sensory changes or weakness in mixed nerves, and need for follow-up.

Treatment Delivery

Imaging Guidance and Technical Considerations

Experts strongly agreed on nearly all technical recommendations. Proper cryoneurolysis requires meticulous imaging guidance, careful probe orientation, and controlled cryogenic delivery for effective and safe nerve ablation [14, 21]. Cryoneurolysis must be performed with precise probe placement under imaging guidance–-ultrasound, CT, or MRI (100% $\geq$ 7). Imaging should confirm the exact nerve location before freezing (95.5% $\geq$ 7), and continuous imaging should be used to monitor the progress and effectiveness of cryoablation (96% $\geq$ 7).

Experts agreed that the cryoprobe should be inserted with minimal trauma and oriented parallel to the nerve to avoid mechanical damage (95.5% $\geq$ 7). Cryogenic energy must be delivered in a controlled manner to protect adjacent tissues (100% $\geq$ 7) with duration and temperature tailored to nerve size and location (91% $\geq$ 7). Achieving a Sunderland II injury for durable pain relief was considered essential (100% $\geq$ 7), and the need to validate protocols ensuring this injury level was emphasized (95% $\geq$ 7). Longer freeze cycles, such as a 12 min single freeze or a 10 + 7 min dual freeze, were viewed as potentially beneficial to guarantee a Sunderland II injury (82% $\geq$ 7). Panelists also noted that visualizing or measuring certain targets, such as celiac or stellate plexi, can be challenging because of their web-like structure (95% $\geq$ 7). For plexus targets that are not directly visualizable (celiac, stellate), operators should rely on established anatomic landmarks, vascular markers, and cross-sectional imaging to position probes appropriately, erring toward broader coverage of the anatomic region rather than precise nerve targeting.

In cases where the specific nerve responsible for pain cannot be identified on imaging—such as small afferent branches infiltrated by tumor—lesion-directed cryoablation targeting the painful mass itself may provide effective pain relief (91% $\geq$ 7). This approach is particularly applicable to metastases $<$ 5 cm where multiple nerve branches are presumed involved. Operators should use larger-diameter tumor ablation probes, aim for complete ice ball coverage of the painful lesion with a 5–10 mm margin, and remain vigilant for adjacent critical structures. In such scenarios, precise probe orientation relative to individual nerves is less critical than achieving complete coverage of the pain-generating region.

Sterile Technique and Prophylactic Antibiotics

The panel unanimously agreed on meticulous sterile technique for all cryoneurolysis procedures (100% $\geq$ 7). However, no consensus was reached on routine prophylactic antibiotics (54% $\geq$ 7), reflecting differing institutional practices. Proponents emphasized severe infection risk near critical structures or in immunocompromised cancer patients. Opponents countered that cryoneurolysis carries low infection risk and non-essential antibiotics contribute to resistance. The panel agreed meticulous sterile technique remains paramount, with individual risk assessment guiding decisions. Consider prophylactic antibiotics for immunocompromise, diabetes, prosthetic devices, prior radiation, or large-bore probes ($>$ 14 gauge) with deep access.

Cryoablation systems vary substantially: argon-based (8–17 gauge), nitrogen-based (9–17 gauge), and carbon dioxide/nitrous oxide (14–24 gauge), affecting probe size, ice ball dimensions, and invasiveness. Large-bore nitrogen probes (9-gauge) typically require moderate to deep sedation for deep targets. Match system selection to clinical scenario: smaller-gauge probes for superficial nerves under local anesthesia, larger systems for deep, complex, or tumor-related targets with sedation support.

Expected Outcomes and Complication Avoidance

Non-Target Ablation Prevention

Experts showed cohesive agreement on key safety measures. Panelists emphasized careful needle insertion to avoid non-target ablation causing allodynia or pain exacerbation (100% $\geq$ 7). They recommended protective techniques using saline, balloons, or gases to displace adjacent tissues and minimize collateral injury (95% $\geq$ 7),

and highlighted awareness of potential side effects including bruising, bleeding, infection, frostbite, alopecia, and depigmentation (91% ≥ 7). Operators must avoid over-ablation by controlling freeze duration to achieve Sunderland II injury (100% ≥ 7). Most experts rely on imaging visualization as temperature probes are not universally available. Operators must remain vigilant for rare myonecrosis (86% ≥ 7).

Operator Training and Outcomes

Panelists stressed that operator training, experience, and case volume significantly influence outcomes, with higher success rates observed among operators with greater procedural experience (100% ≥ 7). The panel supported efforts to standardize protocols to reduce variability and improve consistency across centers and operators (100% ≥ 7).

Post-Treatment Care and Imaging Follow-Up

The panel unanimously recommended tracking pain relief duration and adjusting treatment protocols based on patient response (100% ≥ 7). High-resolution imaging—CT, MRI, or ultrasound—is advised when complications are suspected or symptoms change unexpectedly, but is not required to assess routine nerve response (95% ≥ 7). Routine imaging in asymptomatic patients with satisfactory pain relief is unnecessary.

If unsuccessful or partially effective, a second cryoneurolysis session within 2–4 weeks is appropriate (100% ≥ 7). This timeframe allows assessment before significant axonal regeneration occurs. Persistent inadequate relief after two sessions indicates refractoriness and warrants alternative therapies (95% ≥ 7).

Follow-up imaging is reserved for suspected complications (infection, hematoma, neurologic deficits) or unexpected pain recurrence. Residual pain within 2–4 weeks may reflect incomplete ablation and warrants repeat procedure, while lack of benefit after two sessions signals need for alternatives. The panel suggests structured follow-up at 1 week (complications and initial response), 4 weeks (efficacy and repeat need), 3, 6, and 12 months to characterize benefit duration and guide re-treatment. Repeat cryoneurolysis can be performed with comparable efficacy.

Discussion

This expert consensus provides systematically derived recommendations for cryoneurolysis in pain management. With meticulous patient selection, imaging guidance, and adherence to these precautions, cryoneurolysis offers safe, minimally invasive pain control for malignant and benign conditions [13, 15, 22]. Compared to RFA and chemical neurolysis, cryoneurolysis offers distinct advantages. The visible ice ball allows real-time monitoring, reducing collateral damage risk. The controlled Sunderland II injury with preserved endoneurial sheath permits predictable regeneration and minimizes neuroma formation, a significant complication of phenol or alcohol neurolysis. Patients experience less post-procedural pain due to analgesic rather than irritant effects. However, cryoneurolysis requires more specialized equipment and longer procedure times than RFA [23].

Cryoneurolysis should be the preferred neurolytic technique when equipment and expertise are available, particularly with optimized imaging guidance [24]. It provides effective relief for abdominal, pelvic, and thoracic malignancy-related pain; occipital neuralgia; post-amputation pain; knee osteoarthritis; post-arthroplasty pain; and chronic orchialgia [17, 25]. Prospective studies report durable pain reduction in 50–60% of patients for 6–12 months, with benefits in post-herpetic neuralgia, hip spasticity, obturator neuralgia, and facet syndromes [26]. Advanced imaging improves targeting and outcomes while reducing complications. Considering pain relief duration (5–12 months), reduced opioid consumption, fewer repeat interventions, and avoidance of invasive surgery, cryoneurolysis may prove cost-effective for selected patients. However, equipment costs and procedural complexity may limit widespread adoption. Future research should include economic analyses comparing cryoneurolysis to standard care.

Table 1 summarizes recommendations for clinical practice. Cryoneurolysis should be reserved for localized chronic pain refractory to conservative management with identifiable nerve targets and positive diagnostic blocks. Anesthesia should be individualized based on patient factors and nerve location. Mandatory high-quality imaging (ultrasound, CT, or MRI) must be used throughout. Cryoprobes should be positioned parallel to nerves with 5–10 mm ice ball margins. Freeze duration: 8–10 min single freeze for sensory nerves or dual 5 min cycles for mixed nerves. Adjacent structures should be protected using hydrodissection, balloon displacement, or gas insufflation. Temperatures should be limited to − 20 °C to − 50 °C when monitoring is available. Clinical follow-up at 1, 4, 12, and ≥ 24 weeks. Imaging reserved for suspected complications. Repeat cryoneurolysis within 2–4 weeks for partial responders, transitioning to alternatives after two unsuccessful attempts. Future research should include randomized trials, standardized outcome reporting, economic analyses, optimal freeze protocols, predictors of success, and safety surveillance. International registries would provide real-world data.

This study has several limitations. Single-author development and statement phrasing may introduce bias. System variability affects generalizability. Only interventional radiologists participated; multidisciplinary perspectives are needed. North American/European representation may limit generalizability. Lack of consensus on anatomical restrictions and antibiotics highlights areas requiring investigation.

In conclusion, this consensus establishes cryoneurolysis standards: diagnostic blocks for patient selection, mandatory imaging guidance, individualized freeze protocols targeting Sunderland II injury, and repeat treatment within 2–4 weeks for partial responders. Areas lacking consensus require further investigation.

Supplementary Information The online version contains supplementary material available at https://doi.org/10.1007/s00270-025-04310-5.

Acknowledgements The authors thank the technologists and nursing staff of participating institutions. MSKCC is funded in part through the NIH/NCI Cancer Center Support Grant P30 CA008748.

Disclosures Francois H. Cornelis is a consultant for GE HealthCare and Microbot. Jeffrey P. Guenette receives research funding from the National Institute of Biomedical Imaging and Bioengineering, Agency for Healthcare Research and Quality, and National Institute for Dental and Craniofacial Research. Neil Resnick and Alexa Levey are consultants for Boston Scientific and investors as well as key opinion leaders for Focused Cryo Inc.

Authorship order reflects each contributor's level of involvement in writing, reviewing, bibliographic research, and editing. All authors reviewed the final manuscript, agreed on the content and recommendations, and approved submission. No external funding supported the preparation or writing of this work.

Funding This study was not supported by any funding.

Declarations

Conflict of interest The authors declare that they have no conflict of interest.

Ethical Approval This article does not contain any studies with human participants or animals performed by any of the authors.

Informed Consent For this type of study informed consent is not required.

Consent for Publication For this type of study consent for publication is not required.

References

1. Cornelis FH, Bokhari R, Geevarghese R, Filippiadis DK. Cryoneurolysis: parallel growth in PubMed publications and Google trends analysis reveals exponential interest. Cardiovasc Interv Radiol. 2025;48:1188–92. https://doi.org/10.1007/s00270-025-04118-3.
2. Filippiadis D, Petsatodis E, Charalampopoulos G, et al. Benign soft tissue lesions responsible for pain: when and how should the IR intervene. Cardiovasc Interv Radiol. 2025;48:940–9. https://doi.org/10.1007/s00270-024-03940-5.
3. Filippiadis DK, Cornelis FH, Kelekis A. Interventional oncologic procedures for pain palliation. Presse Med. 2019;48:e251–6. https://doi.org/10.1016/j.lpm.2019.06.006.
4. Moon JT, Li H, Cooper M, et al. Cryoneurolysis as a neuroregenerative intervention for chronic painful mononeuropathies: a four-patient case series and discussion. Cardiovasc Interv Radiol. 2025;48:1499–504. https://doi.org/10.1007/s00270-025-04114-7.
5. Bittman RW, Peters GL, Newsome JM, et al. Percutaneous image-guided cryoneurolysis. AJR Am J Roentgenol. 2018;210:454–65. https://doi.org/10.2214/AJR.17.18452.
6. Filippiadis D, Efthymiou E, Tsochatzis A, et al. Percutaneous cryoanalgesia for pain palliation: current status and future trends. Diagn Interv Imaging. 2021;102:273–8. https://doi.org/10.1016/j.diii.2020.11.007.
7. Filippiadis DK, Tselikas L, Tsitskari M, et al. Percutaneous neurolysis for pain management in oncological patients. Cardiovasc Interv Radiol. 2019;42:791–9. https://doi.org/10.1007/s00270-019-02185-x.
8. Prologo JD, Edalat F, Moussa M. Interventional cryoneurolysis: an illustrative approach. Tech Vasc Interv Radiol. 2020;23:100698. https://doi.org/10.1016/j.tvir.2020.100698.
9. Bodard S, Geevarghese R, Razakamanantsoa L, et al. Percutaneous cryoablation in soft tissue tumor management: an educational review. Insights Imaging. 2024;15:278. https://doi.org/10.1186/s13244-024-01822-5.
10. Bodard S, Marcelin C, Kastler A, et al. Safety and efficacy of cryoablation of soft-tissue tumours: a systematic review. Br J Radiol. 2025;98:861–74. https://doi.org/10.1093/bjr/tqae075.
11. Filippiadis DK, Prologo D. Percutaneous cryoneurolysis: is it possible to standardize the ablation protocol? Cardiovasc Interv Radiol. 2023;46:813–4. https://doi.org/10.1007/s00270-023-03396-z.
12. Bittman RW, Behbahani K, Gonzalez F, Prologo JD. Interventional cryoneurolysis: what is the same, what is different, what is new? Semin Intervent Radiol. 2019;36:374–80. https://doi.org/10.1055/s-0039-1696705.
13. Prologo JD, Johnson C, Hawkins CM, et al. Natural history of mixed and motor nerve cryoablation in humans-a cohort analysis. J Vasc Interv Radiol. 2020;31:912-916.e1. https://doi.org/10.1016/j.jvir.2019.11.026.
14. Sag AA, Bittman R, Prologo F, et al. Percutaneous image-guided cryoneurolysis: applications and techniques. Radiographics. 2022;42:1776–94. https://doi.org/10.1148/rg.220082.
15. Said ET, Marsh-Armstrong BP, Fischer SJ, et al. Relative effects of various factors on ice ball formation and ablation zone size during ultrasound-guided percutaneous cryoneurolysis: a laboratory investigation to inform clinical practice and future research. Pain Ther. 2023;12:771–83. https://doi.org/10.1007/s40122-023-00497-y.
16. Cornelis AA, Bodard S, Cornelis FH. Lethal isotherm ratio to standardize the comparison of cryoablation needles and systems. CVIR Oncol. 2025;1:3. https://doi.org/10.1007/s44343-025-00004-4.
17. Kelekis A, Cornelis FH, Tutton S, Filippiadis D. Metastatic osseous pain control: bone ablation and cementoplasty. Semin Intervent Radiol. 2017;34:328–36. https://doi.org/10.1055/s-0037-1608747.
18. Chang DL, Mirman B, Mehta N, Pak D. Applications of cryoneurolysis in chronic pain management: a review of the current literature. Curr Pain Headache Rep. 2024;28:403–16. https://doi.org/10.1007/s11916-024-01222-w.

19. Daubié S, Pilleul F, Thivolet A, et al. Cryoneurolysis in patients with dorsal neuropathic pain secondary to tumor invasion. J Vasc Interv Radiol. 2020;31:917–24. https://doi.org/10.1016/j.jvir.2020.01.018.
20. Biel E, Aroke EN, Maye J, Zhang SJ. The applications of cryoneurolysis for acute and chronic pain management. Pain Pract. 2023;23:204–15. https://doi.org/10.1111/papr.13182.
21. Cha PI, Min JG, Patil A, et al. Efficacy of intercostal cryoneurolysis as an analgesic adjunct for chest wall pain after surgery or trauma: systematic review. Trauma Surg Acute Care Open. 2021;6:e000690. https://doi.org/10.1136/tsaco-2021-000690.
22. Finneran Iv JJ, Schaar AN, Swisher MW, et al. Percutaneous cryoneurolysis of the lateral femoral cutaneous nerve for analgesia following skin grafting: a randomized, controlled pilot study. Reg Anesth Pain Med. 2022;47:60–1. https://doi.org/10.1136/rapm-2021-102931.
23. Vroomen LGPH, Petre EN, Cornelis FH, et al. Irreversible electroporation and thermal ablation of tumors in the liver, lung, kidney and bone: what are the differences? Diagn Interv Imaging. 2017;98:609–17. https://doi.org/10.1016/j.diii.2017.07.007.
24. Cornelis FH, Filippiadis DK, Wiggermann P, et al. Evaluation of navigation and robotic systems for percutaneous image-guided interventions: a novel metric for advanced imaging and artificial intelligence integration. Diagn Interv Imaging. 2025;106:157–68. https://doi.org/10.1016/j.diii.2025.01.004.
25. Nygaard N-PB, Koch-Jensen C, Vaegter HB, et al. Efficacy of cryoneurolysis on chronic pain in patients with knee osteoarthritis: a double-blinded randomized controlled sham trial. Anesthesiology. 2025;142:1114–26. https://doi.org/10.1097/ALN.0000000000005396.
26. Cahani D, Chacko J, Hahn B. Myonecrosis: a rare complication of cryoneurolysis. J Emerg Med. 2019;57:e73–6. https://doi.org/10.1016/j.jemermed.2019.06.017.

Publisher's Note Springer Nature remains neutral with regard to jurisdictional claims in published maps and institutional affiliations.

Springer Nature or its licensor (e.g. a society or other partner) holds exclusive rights to this article under a publishing agreement with the author(s) or other rightsholder(s); author self-archiving of the accepted manuscript version of this article is solely governed by the terms of such publishing agreement and applicable law.